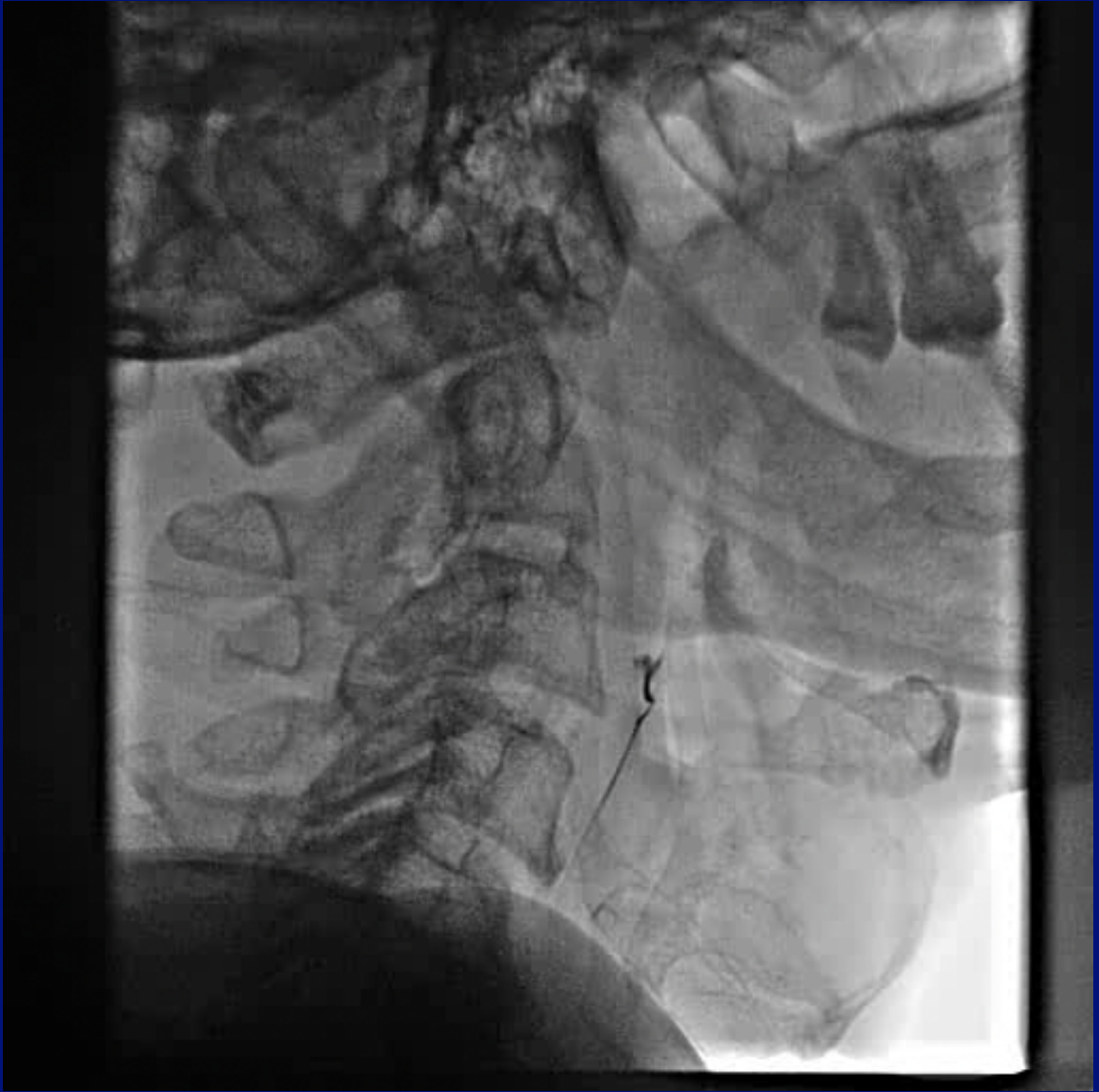

Filling Defect after Carotid Stenting

Dr Sajid Yoonus
Consultant Cardiologist
MIMS, Kozhikode

- 64 yr old diabetic, hypertensive
- CSA class II, TVD (CAG in 2007), normal LV, on medical management
- Recurrent TIA of few weeks
 - Left hemiparesis/brachial monoparesis
>5 episodes
 - Right amaurosis fugax – 1 episode

- Carotid Doppler – thrombotic lesion with 90% stenosis of proximal Right ICA
- Angiogram – >90% stenosis of proximal Right ICA

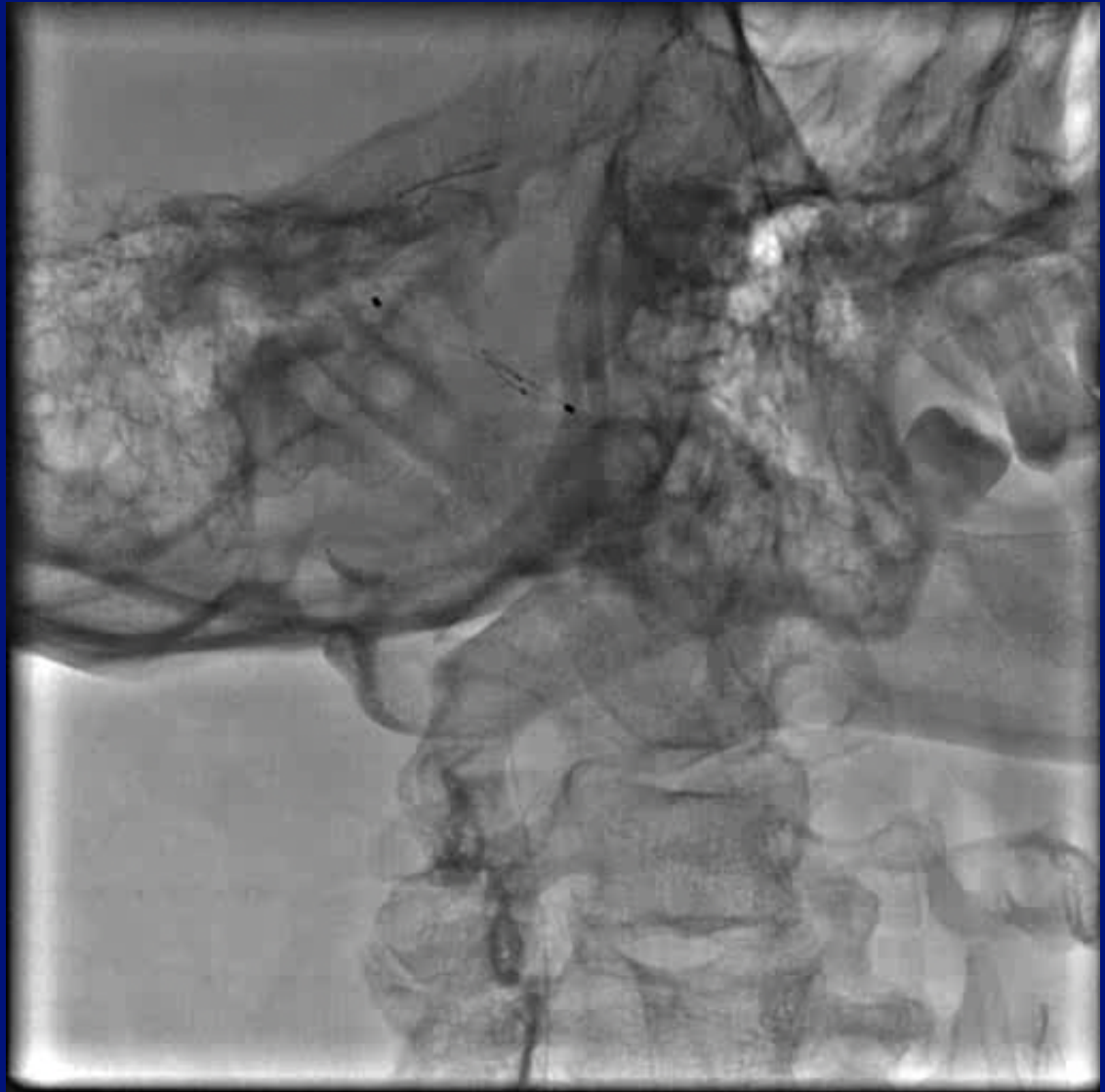


- Planned for carotid stenting
- Decided to heparinise for one week;
Enoxaparin 60 mg sc twice daily
- Dual antiplatelets

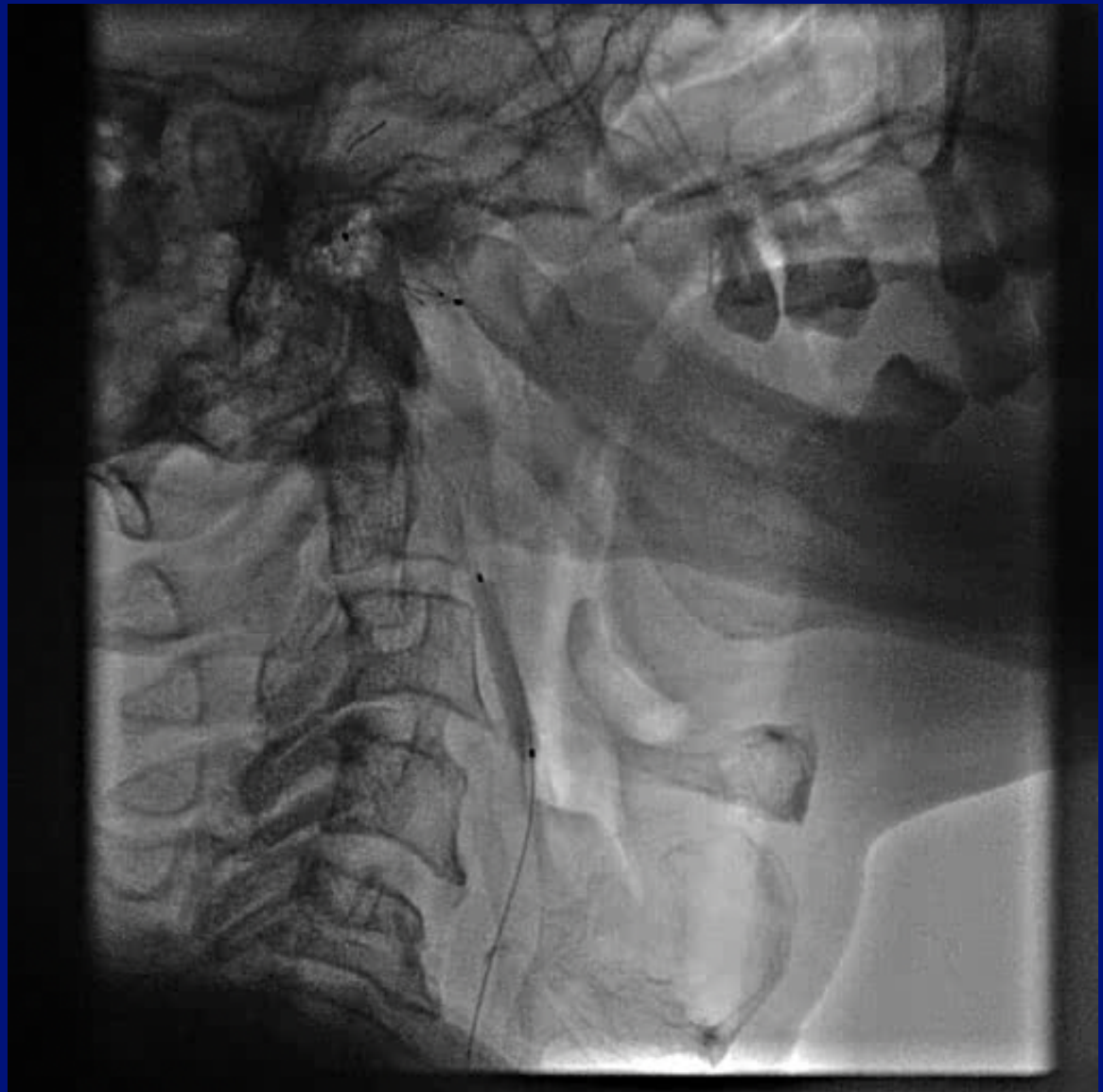7F Long Sheath

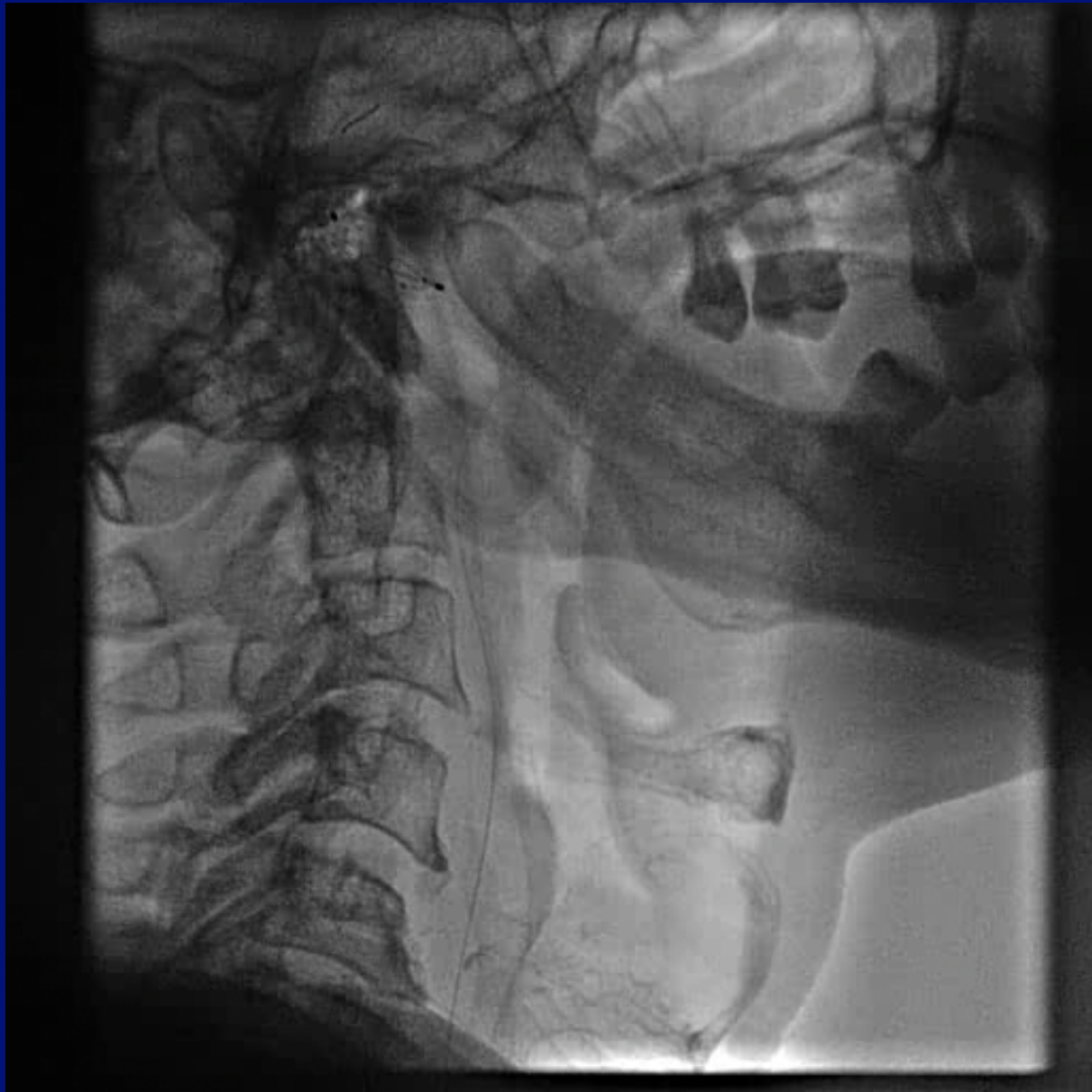
Galeo floppy wire

Distal protection
(SpiderFX 6.0mm)



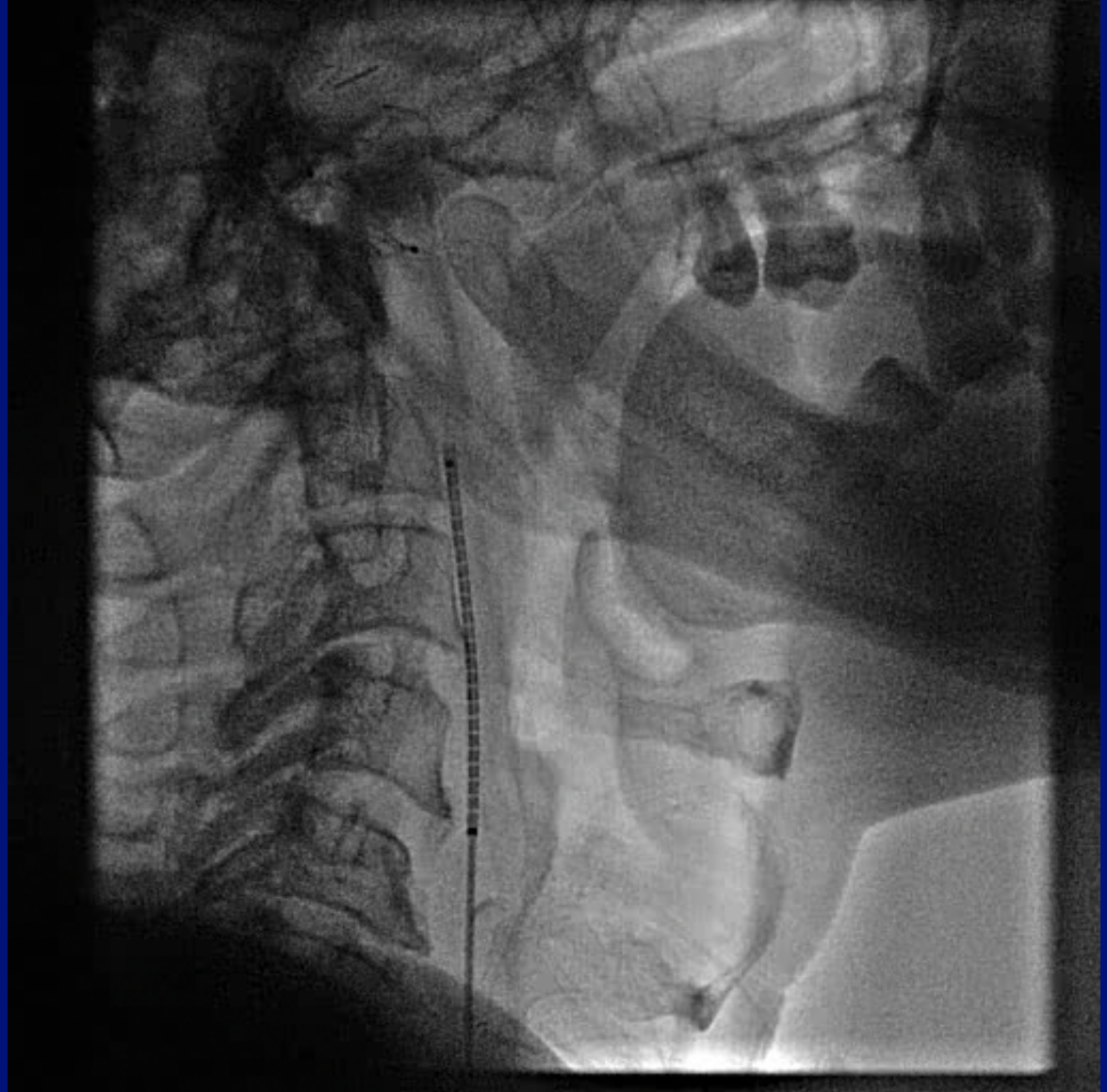
Pre-dilatation
4x20 balloon





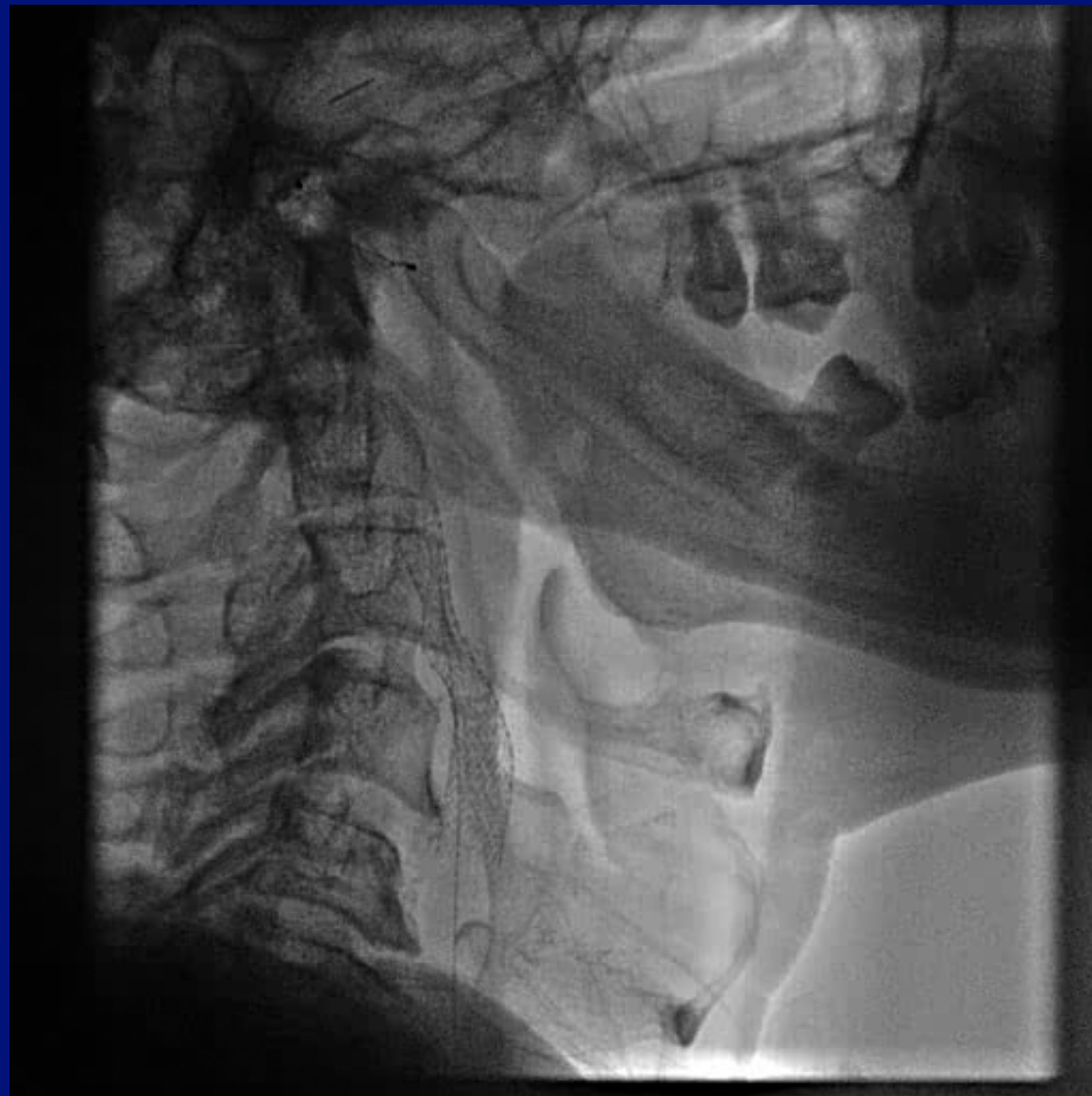
8x40 Precise Stent

(Self-expanding
Nitinol stent)
(Cordis)



Prolapsing
thrombus/plaque

ACT optimal



Persistent lesion
20 min

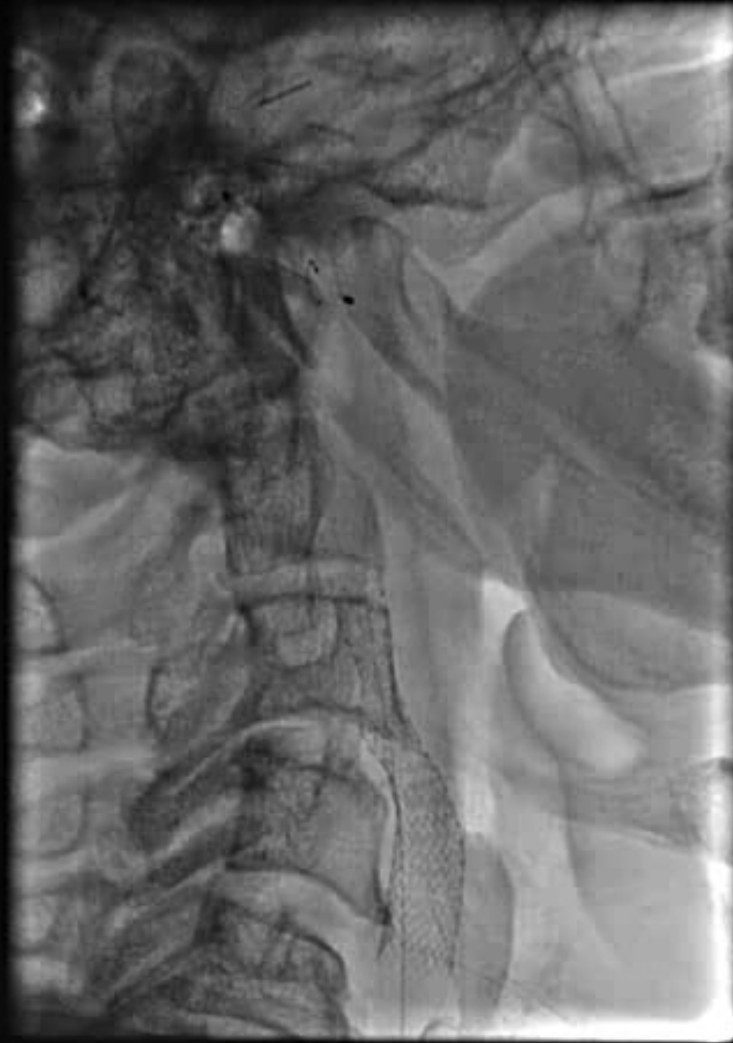
What next?
Options considered

Stop procedure

Post-dilatation

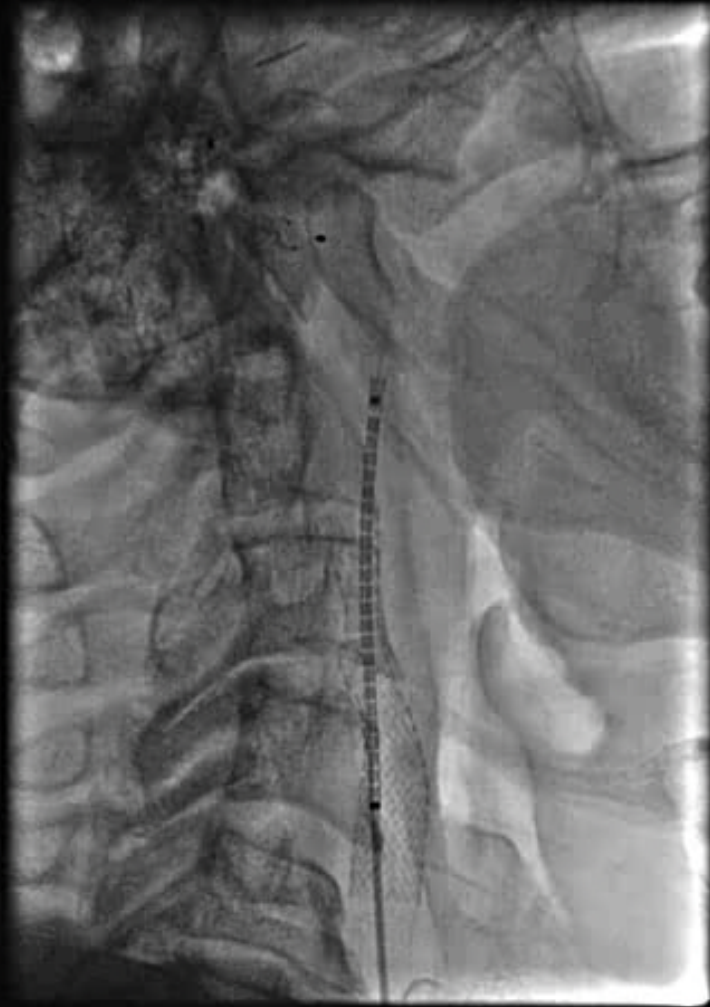Second Stent

Gp2b3a-I



iv Tirofiban

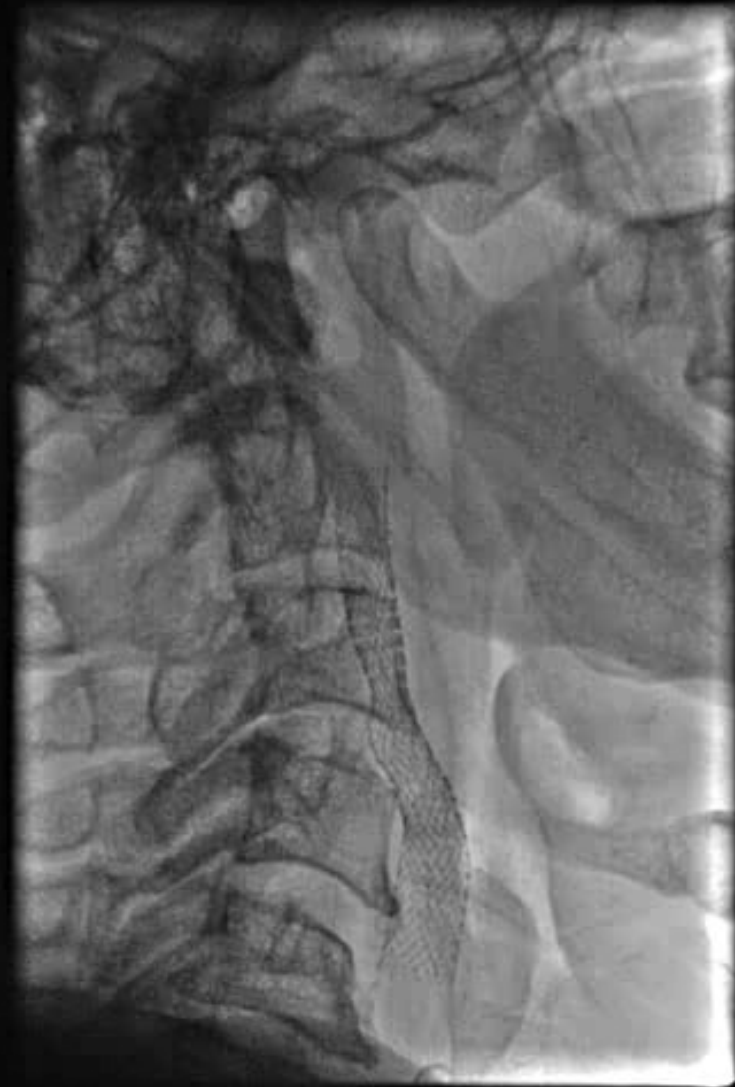7X40 Precise Stent



Better ?

No post-dilatation

Filter removed



- Left brachial monoplegia soon after procedure; recovered in 10-15 min
- Recurrence of TIA few hrs later
- Tirofiban continued for 48 hrs
- Heparinized for 5 days
- Discharged with no deficits
- Doing well on follow-up