

“Case of AVM”

Dr. Shifas Babu. M

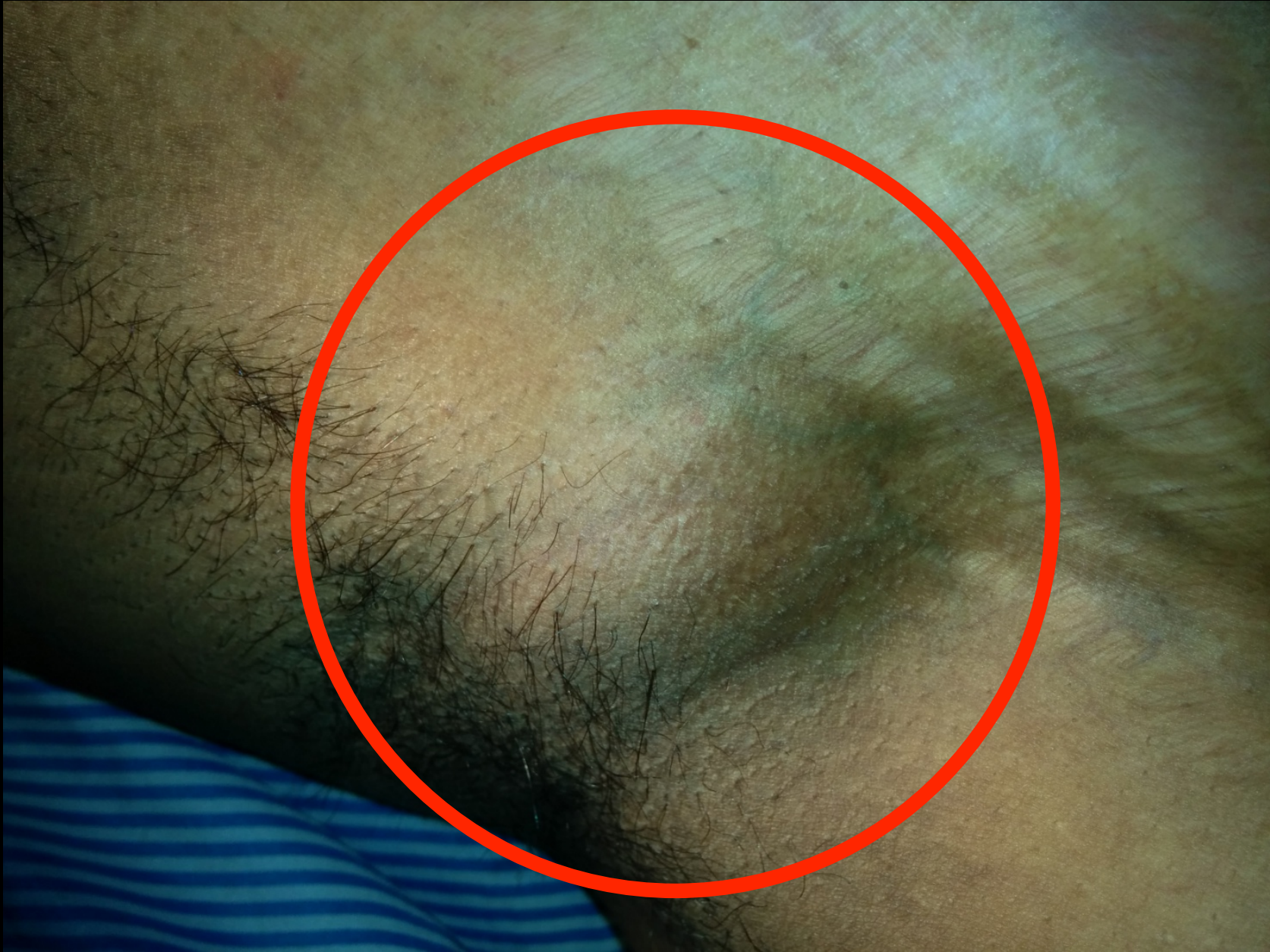CardioVascular Centre
Ananthapuri Hospitals and Research Institute
Thiruvananthapuram

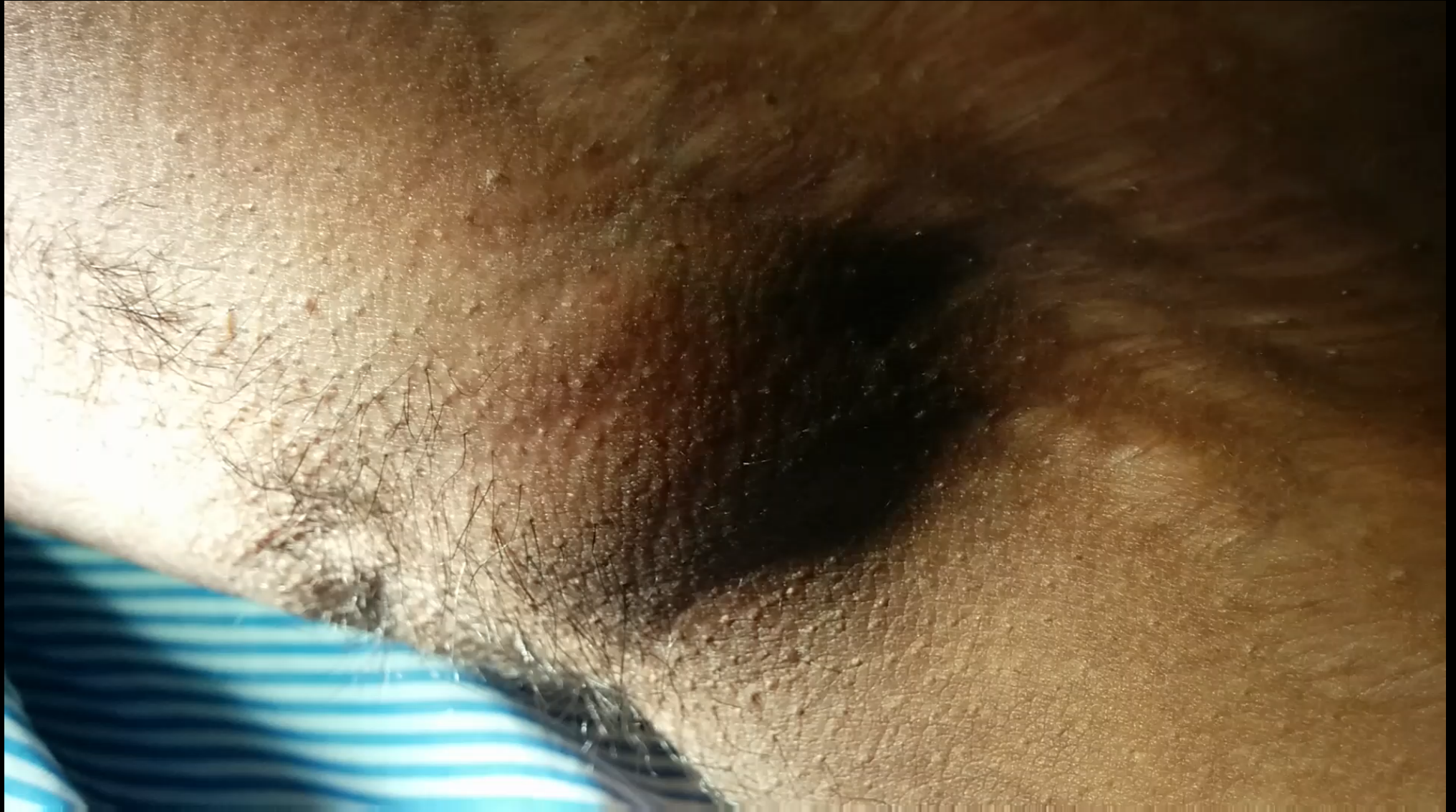

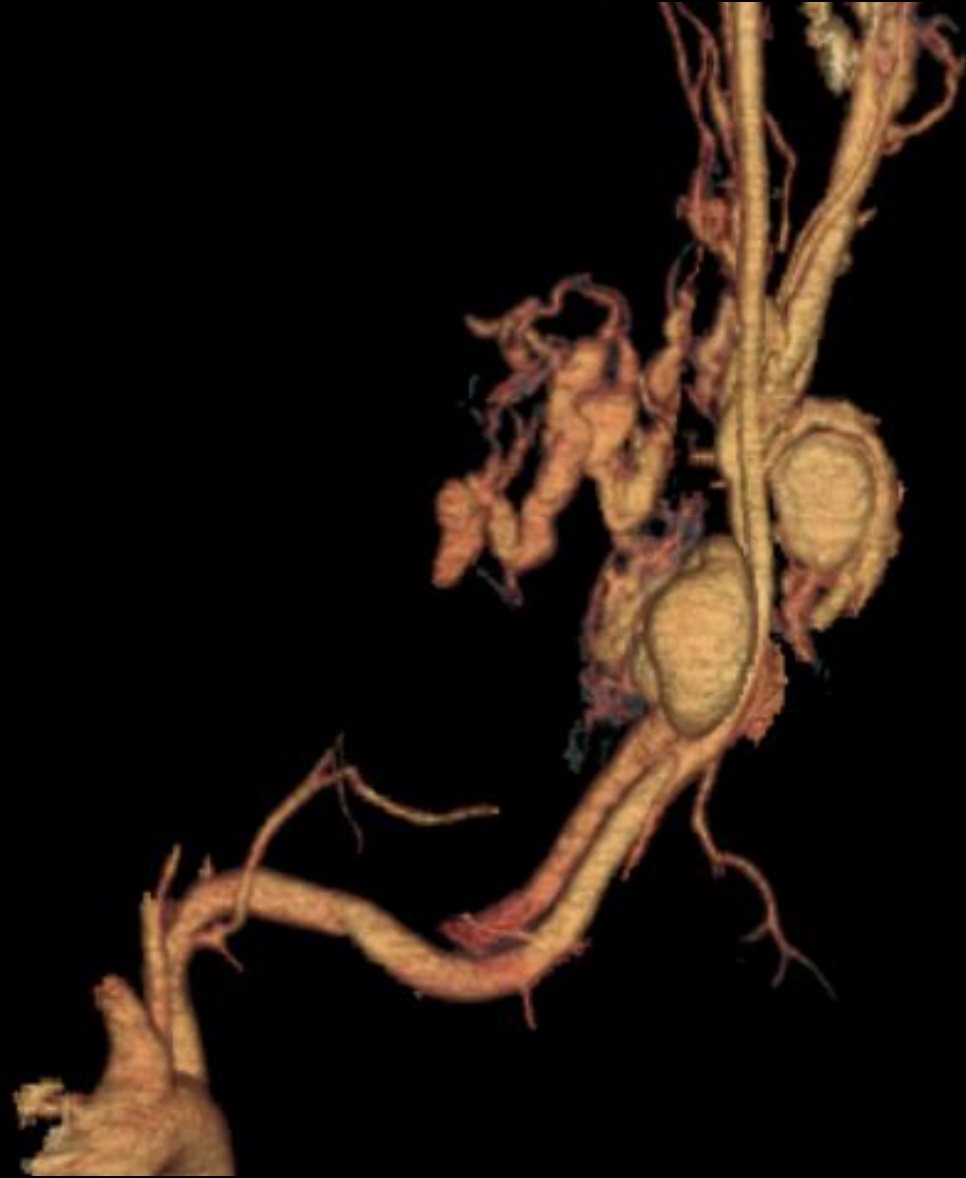The Patient...

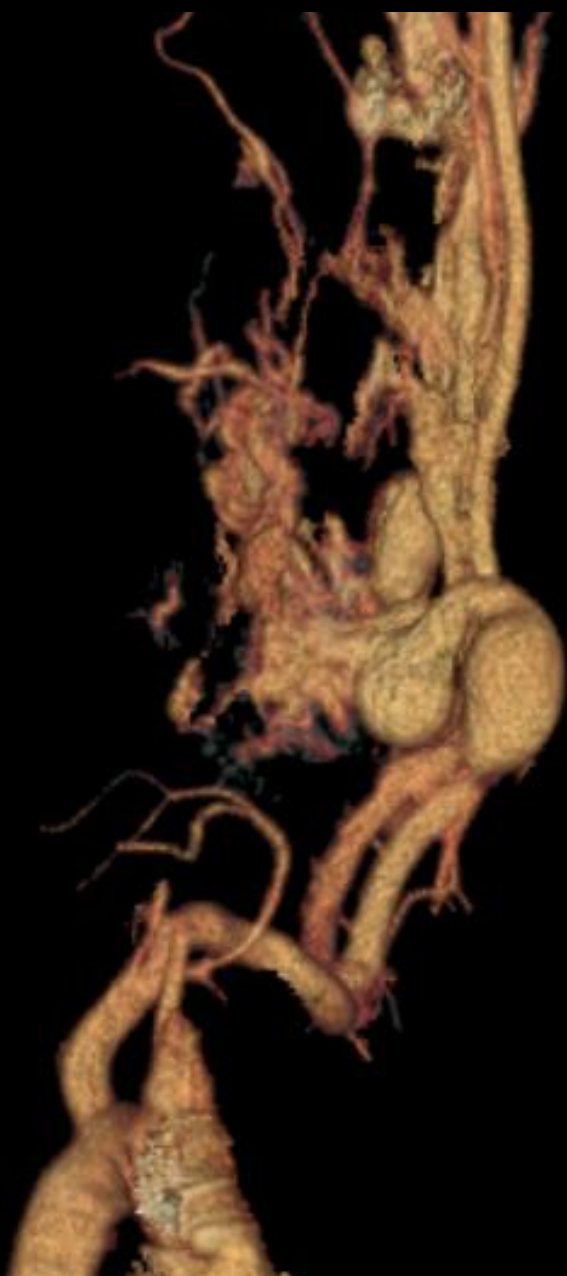- 28 year old man
- No co-morbidities

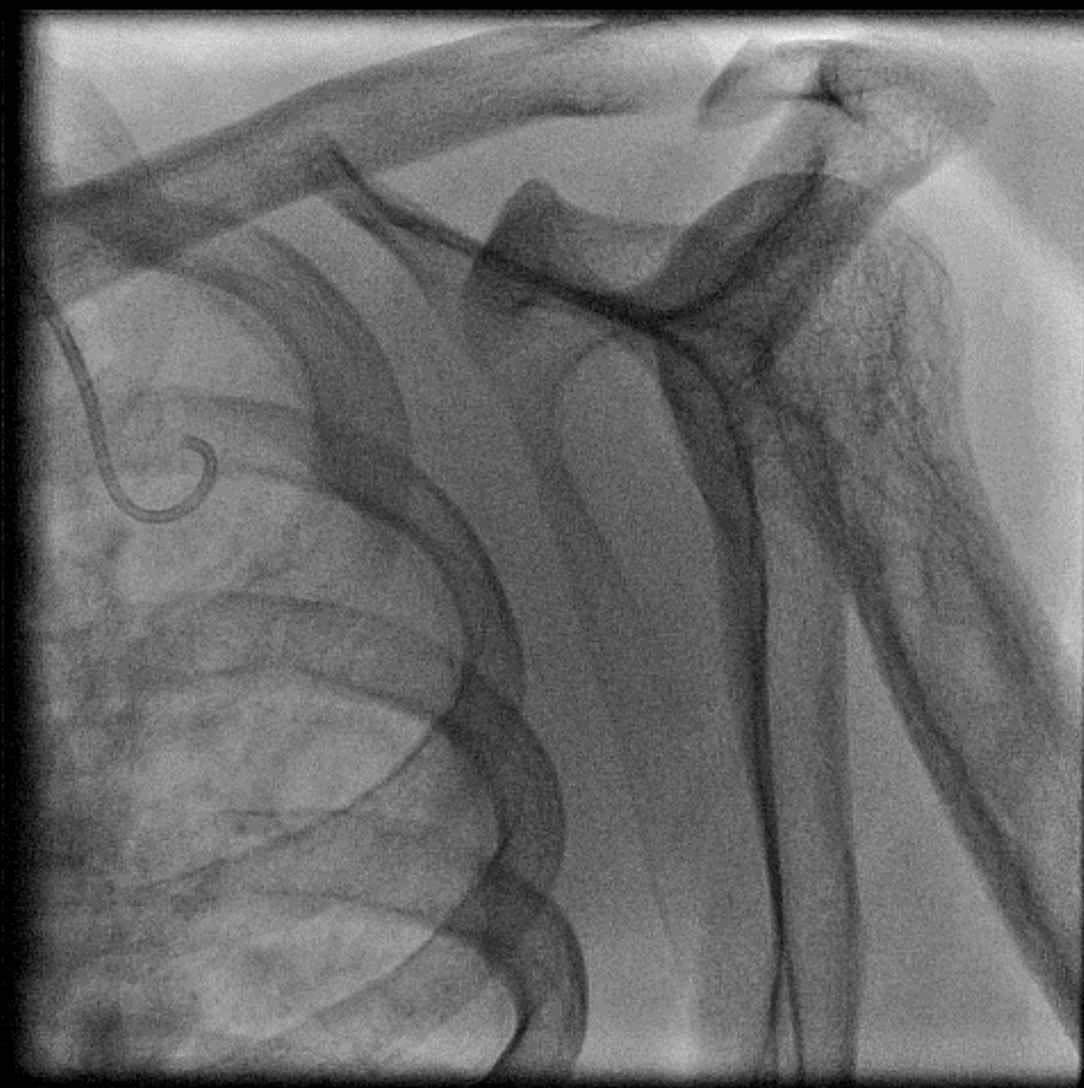- Presented with progressively increasing pulsatile mass in the left axilla
- Small swelling noted 2 years back-gradually increased in size .
- Forearm claudication

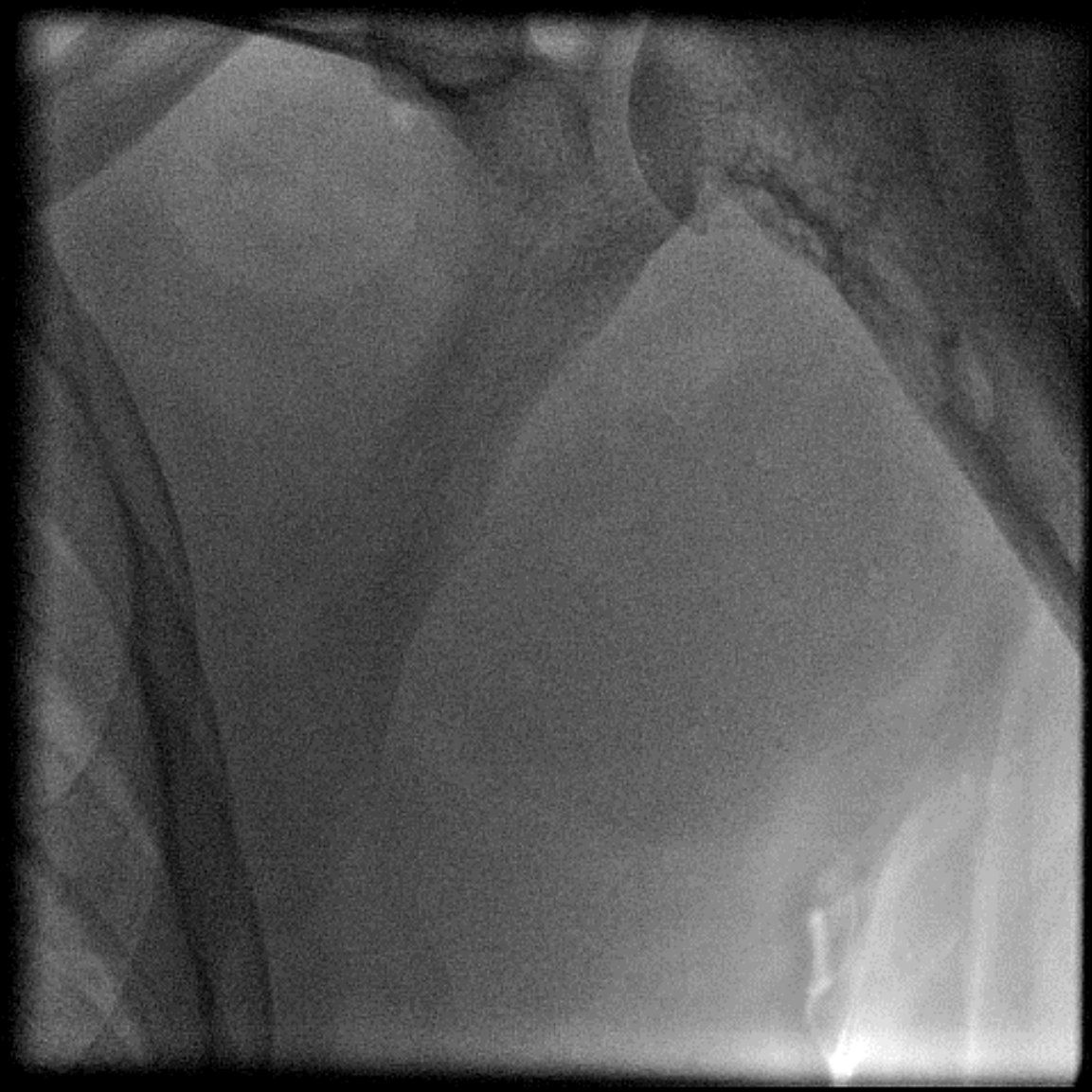


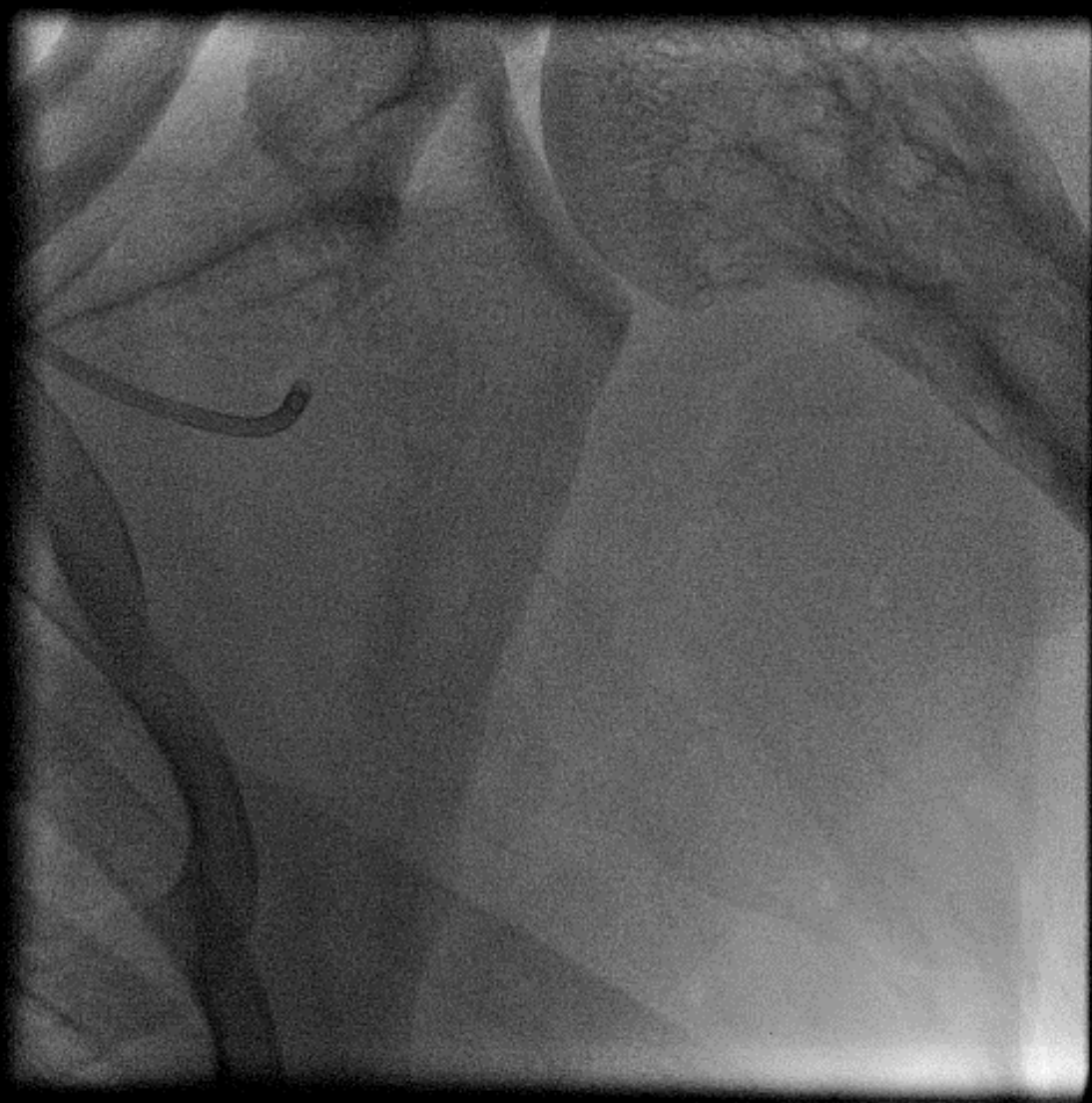


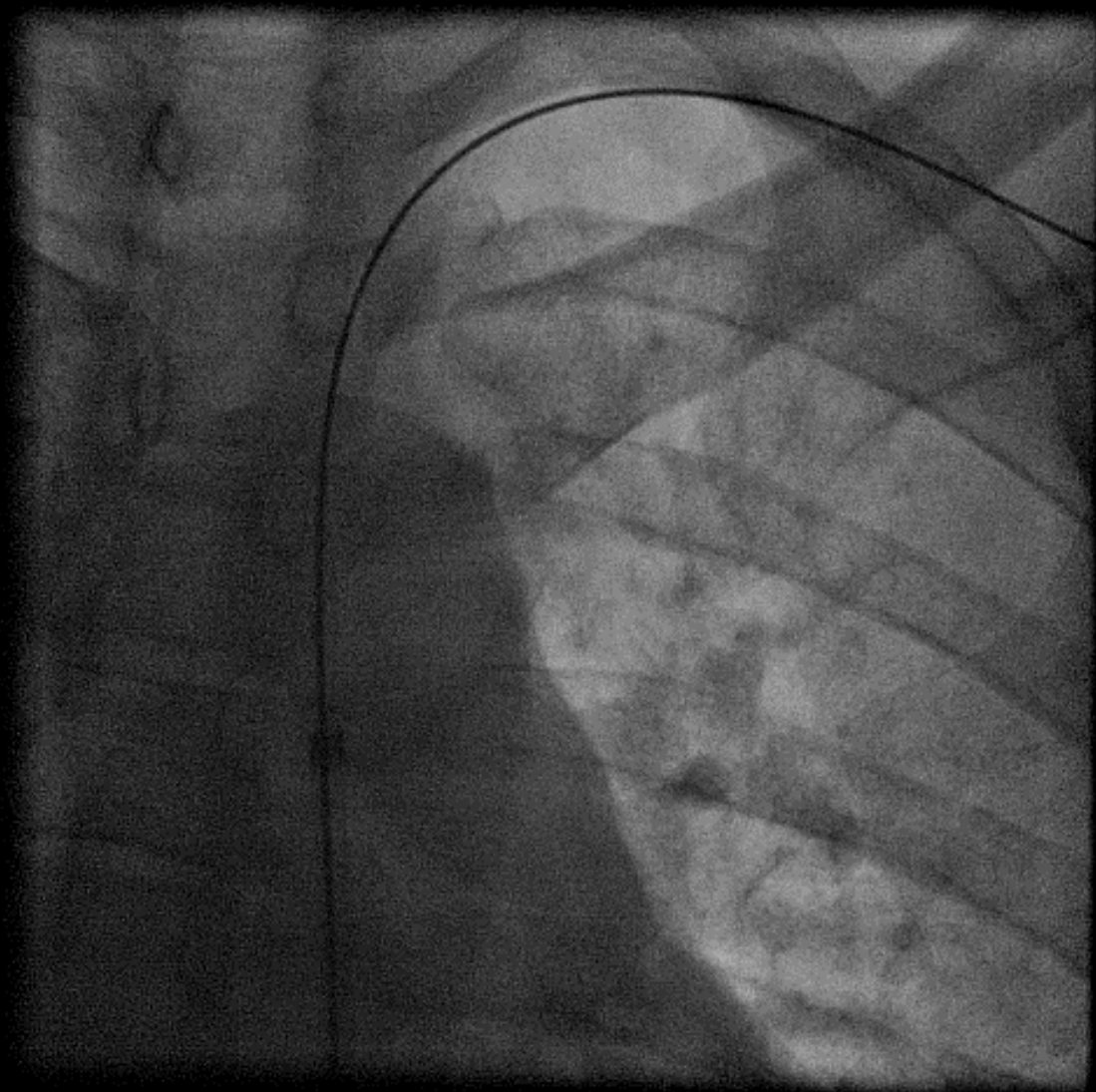




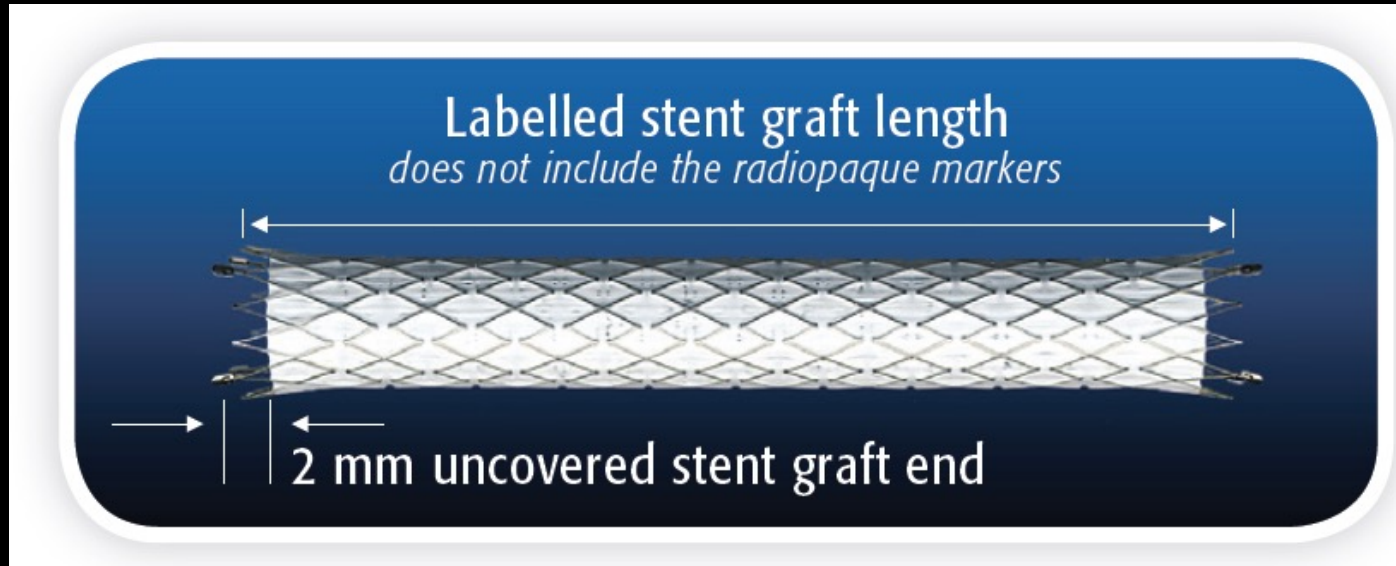

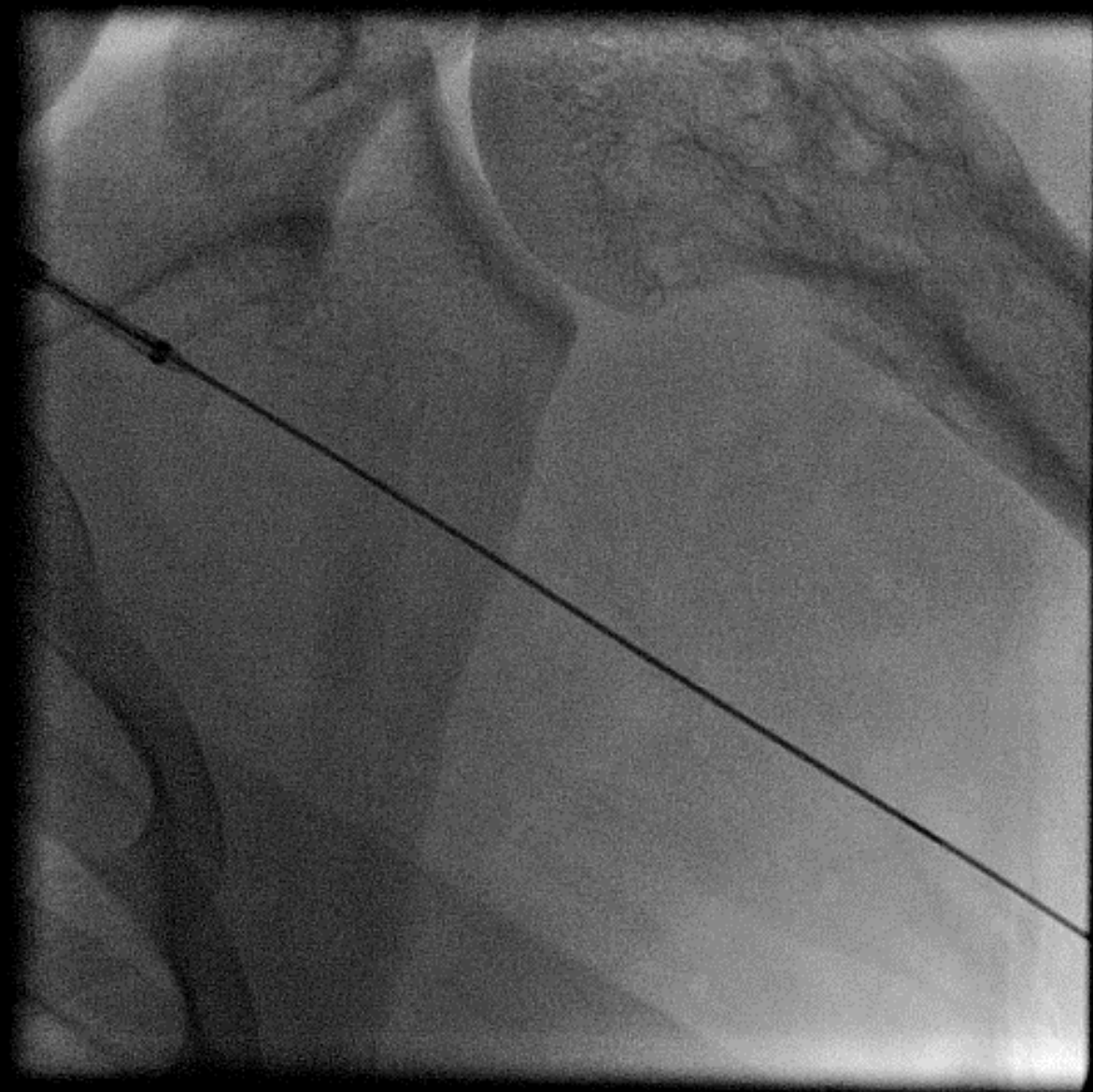


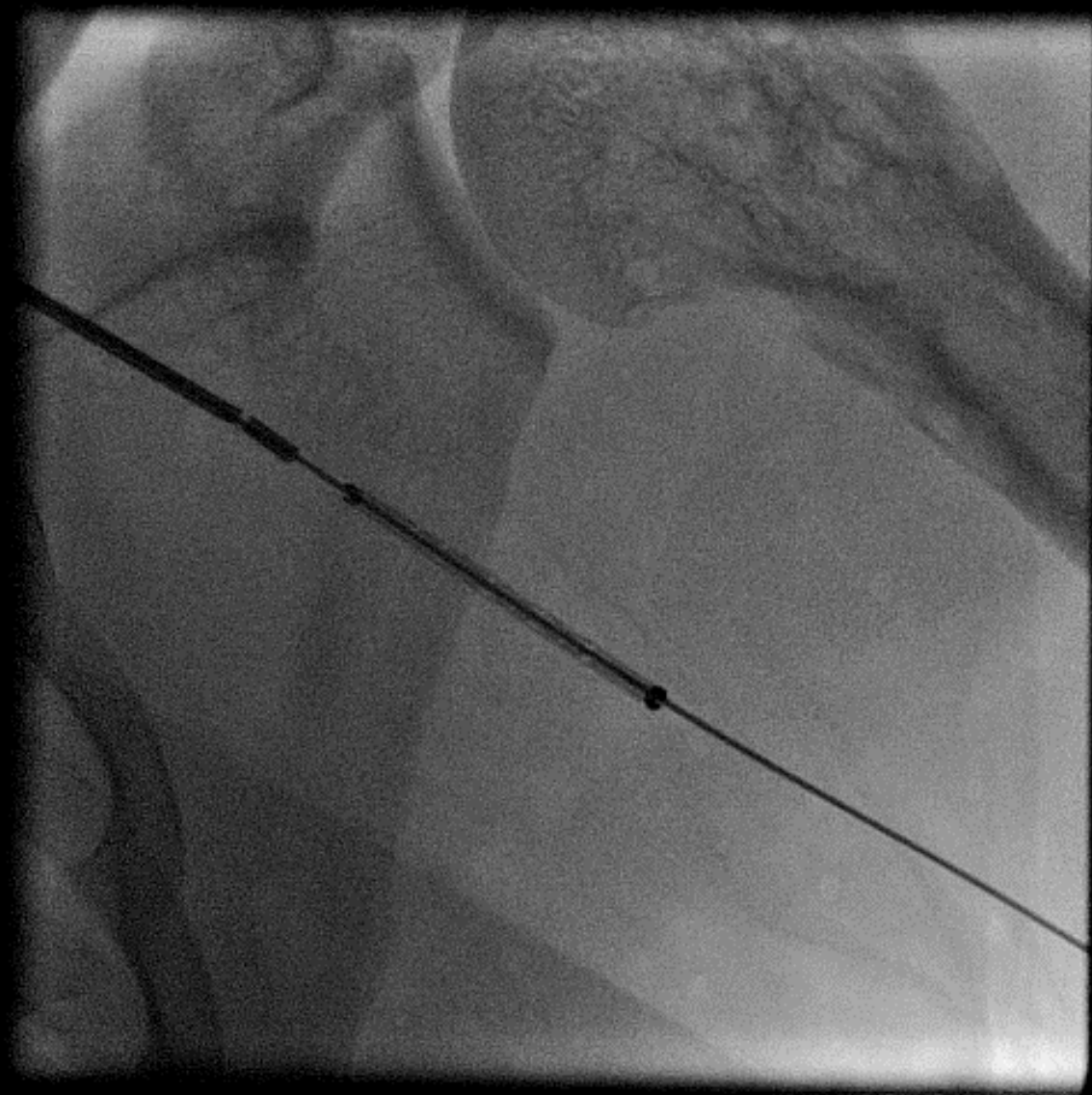


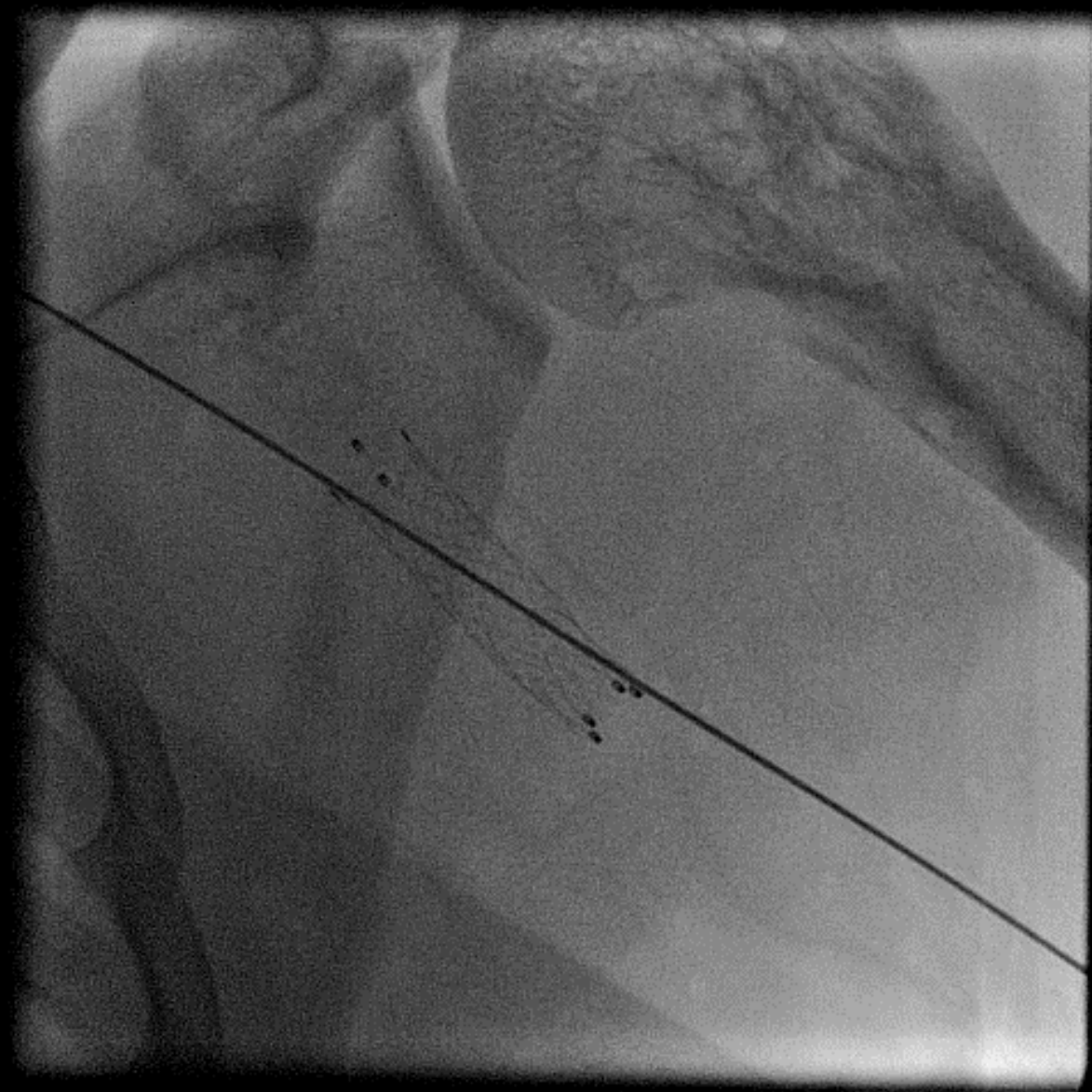


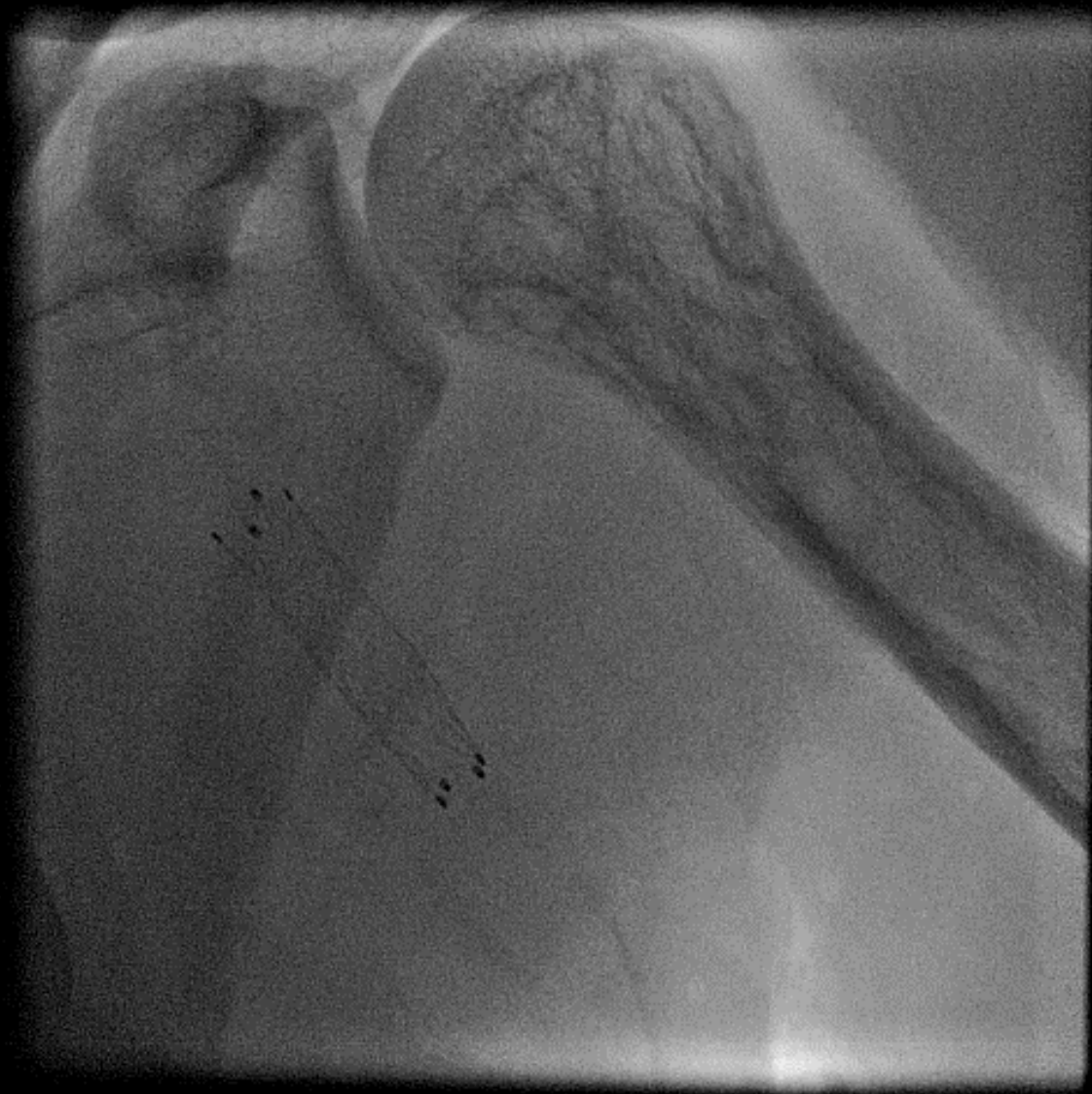10 x 40 mm
Fluency plus
Self Expanding Stent Graft

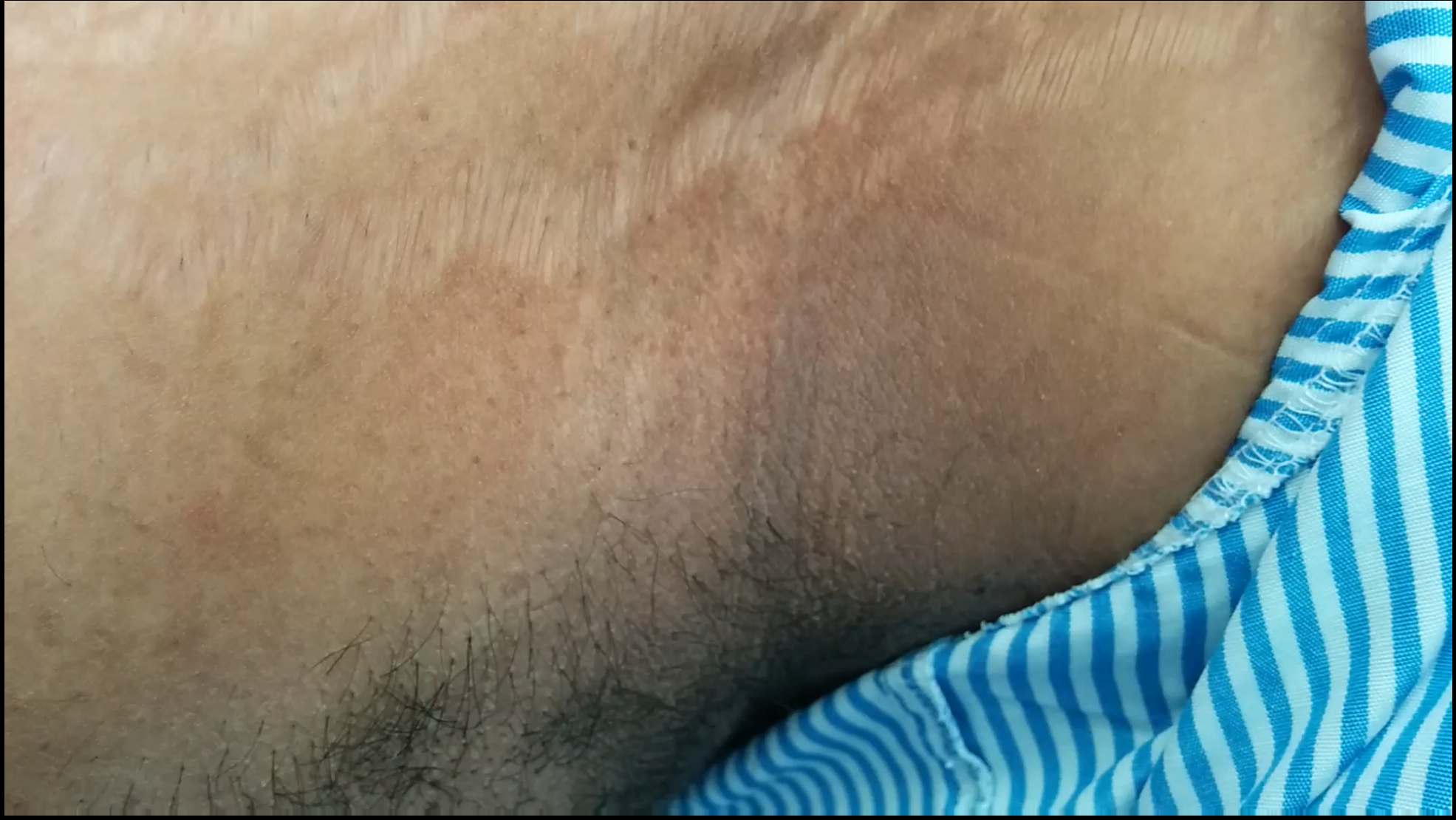




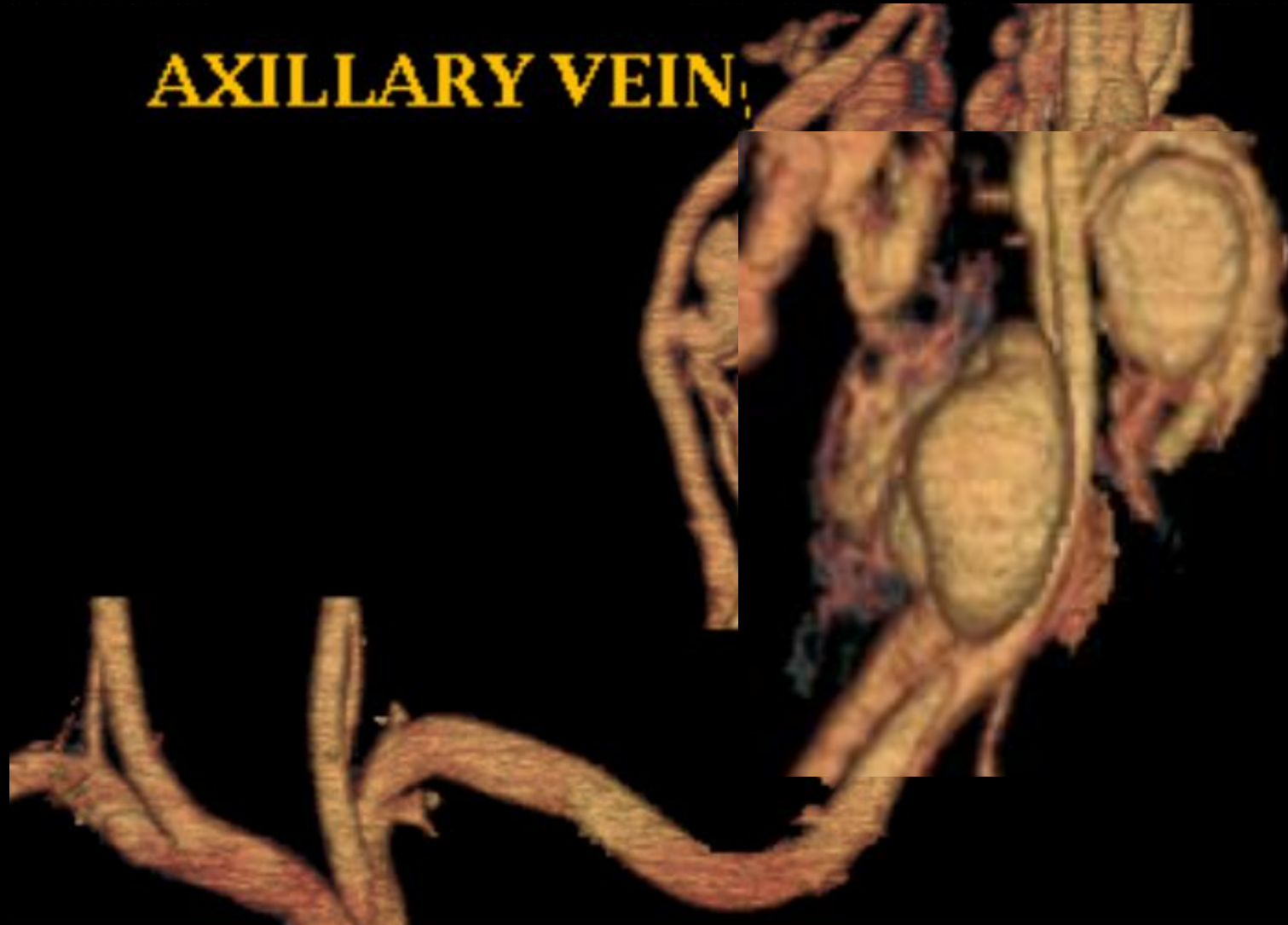






AXILLARY VEIN





THANK YOU...